



FULL LENGTH ARTICLE

Phenotypic characterization of patients with activated PI3K δ syndrome 1 presenting with features of systemic lupus erythematosus

Yanping Wang^{a,b,c}, Qiuyun Yang^{a,b,c}, Xuemei Chen^{a,b,c},
Wenjing Tang^d, Lina Zhou^{a,b,c}, Zhi Chen^{a,b,c}, Yunfei An^d,
Zhiyong Zhang^d, Xuemei Tang^d, Xiaodong Zhao^{a,b,c,d,*}

^a National Clinical Research Center for Child Health and Disorders (Chongqing), Children's Hospital of Chongqing Medical University, Chongqing, 400014, PR China

^b China International Science and Technology Cooperation Base of Child Development and Critical Disorders, Children's Hospital of Chongqing Medical University, Chongqing, 400014, PR China

^c Chongqing Key Laboratory of Child Infection and Immunity, Children's Hospital of Chongqing Medical University, Chongqing, 400014, PR China

^d Division of Rheumatology and Immunology, Children's Hospital of Chongqing Medical University, Chongqing, 400014, PR China

Received 31 December 2019; accepted 22 April 2020

Available online 30 April 2020

KEYWORDS

Activated phosphoinositide 3-kinase δ syndrome 1; Autoimmune disease; Immunosuppressive therapy; PIK3CD; Systemic lupus erythematosus

Abstract Activated phosphoinositide 3-kinase δ syndrome 1 (APDS1) is a primary immunodeficiency disease caused by gain-of-function mutations in *PIK3CD*. Clinical features of autoimmune disease have been reported in patients with APDS1. In this study, we reported three patients with APDS1 presenting with systemic lupus erythematosus (SLE) phenotype. The clinical manifestations included recurrent respiratory tract infection, lymphoproliferation, Coombs-positive hemolytic anemia, decreased complement fractions, positive antinuclear antibodies, renal complications related to SLE associated diseases, which met the clinical spectrum of APDS1 and the classification criteria of SLE. The immunological phenotype included an inversion in the CD4:CD8 ratio, an increase in both non-circulating Tfh CD4⁺ memory T and circulating Tfh populations, a low level of recent thymic emigrant T cells, overexpression of CD57 on T cells, and a decrease in B cells with fewer antibody class switch recombination. These phenotypes detected in patients with APDS1 presenting with SLE were resemble that

* Corresponding author. Pediatric Research Institute, Chongqing Key Laboratory of Child Infection and Immunity, Ministry of Education Key Laboratory of Child Development and Disorders, National Clinical Research Center for Child Health and Disorders, #136, Zhongshan 2nd Road, Yuzhong District, Chongqing, 400014, PR China. Tel.: +86 23 63630602; fax: +86 23 63602136.

E-mail address: zhaoxd530@aliyun.com (X. Zhao).

Peer review under responsibility of Chongqing Medical University.

in patients with APDS1 presenting without SLE. Meanwhile, we described the effect of glucocorticoids and rapamycin therapy on patients with APDS1. The phosphorylation of S6 at Ser235/236 was inhibited in patients with APDS1 who underwent glucocorticoids therapy, including two who presented with SLE phenotype. The phosphorylation of AKT at Ser473 and phosphorylation of S6 at Ser235/236 were inhibited in other patients with APDS1 who underwent rapamycin therapy. Here, we showed the coexistence of immunodeficiency and SLE phenotype in APDS1, and the inhibition of rapamycin in activated Akt-mTOR signaling pathway.

Copyright © 2020, Chongqing Medical University. Production and hosting by Elsevier B.V. This is an open access article under the CC BY-NC-ND license (<http://creativecommons.org/licenses/by-nc-nd/4.0/>).

Introduction

Activated phosphoinositide 3-kinase δ syndrome 1 (APDS1) is a newly defined primary immunodeficiency disease (PID) caused by gain-of-function (GOF) mutation in *PIK3CD*, which encodes the p110 δ catalytic subunit of phosphoinositide 3-kinase δ (PI3K δ).¹ The p110 δ is expressed predominantly in leukocytes and plays an important role in lymphocyte proliferation, survival, and activation.² *PIK3CD* GOF mutation increases PI3K δ activity, which leads to the increased phosphorylation of AKT and mammalian target of rapamycin (mTOR).¹ Patients with APDS1 present a spectrum of clinical manifestations, but the majority of patients present with recurrent respiratory tract infections, persistent benign lymphadenopathy, chronic *Epstein–Barr virus* (EBV) and *cytomegalovirus* (CMV) infections, autoimmune and inflammatory diseases, and increased susceptibility to lymphoma.^{3–5} APDS2 resembles APDS1, which is caused by GOF mutations in *PIK3R1* gene encoding the p85 α regulatory subunit of PI3K δ , leading to hyperactivated PI3K δ signaling in lymphocytes.⁶ Approximately 28% of patients with APDS (APDS1 and APDS2) present with autoimmune and inflammatory diseases, including hematological, gastrointestinal, rheumatologic, endocrine, and dermatologic disorders.⁴ To date, only one case of systemic lupus erythematosus (SLE) disease has been described in patients with APDS1.^{4,7}

SLE is a multifactorial disease caused by different genetic, immunologic, and environmental factors. It is a systemic autoimmune disease characterized by production of autoantibodies, and tissue inflammation and damage to various organs caused by the deposition of immune complexes.⁸ Certain PIDs have been consistently associated with SLE or lupus-like disease. Lupus-like phenotypes can be observed in complement deficiencies and chronic granulomatous disease, that is caused by aberrant apoptotic cell clearance and leads to an inability to kill pathogens.⁹ Hyper-IgE syndrome and A20 haploinsufficiency are also associated with lupus-like disease.^{10,11} However, the exact pathogenesis of SLE development remains unknown in these cases.

In this study, we reviewed three patients with GOF *PIK3CD* characterized by SLE phenotype, and summarized their clinical history, immunological features, and treatment. We aimed to clarify the understanding of the development of SLE phenotype in APDS1.

Materials and methods

Patients

From 2015 to 2018, three Chinese patients with APDS1 (p.E1021K) who presented with SLE phenotype, and other four Chinese patients with APDS1 (p.E1021K) who presented without SLE phenotype were enrolled in this study. Informed consent was obtained from all individuals before sample collection. This study was conducted in accordance with the tenets of the Declaration of Helsinki and was approved by the ethics committee of Chongqing Medical University (Chongqing, China).

Genetic analyses

Genomic DNA was isolated from peripheral leukocytes and oral mucosa cells using the QIAamp DNA Mini Kit (Qiagen, Germany) according to the manufacturer's instructions. Polymerase chain reaction was performed to amplify *PIK3CD*. The primer sequences used to target exon 24 of *PIK3CD* were F: 5'-ATGTGAGAAGGTGGGATGGG-3' and R: 5'-CGTTTCCGTTTATGGCTGTT-3'. The PCR products were sequenced by Sangon Biotech (Shanghai, China).

Flow cytometry

The following antibodies were used for phenotyping the lymphocytes: anti-CD45 (clone HI30), anti-CD3 (clone UCHT1), anti-CD4 (clone RPA-T4), anti-CD8 (clone RPA-T8), anti-CD45RA (clone HI100), anti-CD27 (clone M-T271), anti-CD31 (clone WM59), anti-CXCR3 (clone G025H7), anti-CCR6 (clone G034E3), anti-CXCR5 (clone RF8B2), anti-CD25 (clone BC96), anti-CD127 (clone A019D5), anti-CD57 (clone NK-1), anti-CD19 (clone HIB19), anti-CD24 (clone ML5), anti-CD38 (clone HIT2), anti-IgD (clone IA6-2), anti-IgG (clone G18-145), all antibodies were purchased from BD Biosciences (San Jose, CA, USA); Anti-IgA (clone IS11-8E10) was purchased from Miltenyi Biotec (Bergisch Gladbach, Germany). The gating strategy for T and B cell subpopulations was as follows: CD4⁺ naïve T cells (CD3⁺CD4⁺CD45RA⁺CD27⁺), CD4⁺ central memory T cells (CD4⁺ CM, CD3⁺CD4⁺CD45RA⁺CD27⁺), CD4⁺ effector memory T cells (CD4⁺ EM, CD3⁺CD4⁺CD45RA⁺CD27⁺), CD4⁺ Temra cells (CD3⁺CD4⁺CD45RA⁺CD27⁺), CD8⁺ naïve T cells

(CD3⁺CD8⁺CD45RA⁺CD27⁺), CD8⁺ central memory T cells (CD8⁺ CM, CD3⁺CD8⁺CD45RA⁺CD27⁺), CD8⁺ effector memory T cells (CD8⁺ EM, CD3⁺CD8⁺CD45RA⁺CD27⁺), CD8⁺ Temra T cells (CD3⁺CD8⁺CD45RA⁺CD27⁺), transitional B cells (CD19⁺CD24⁺⁺CD38⁺⁺), naïve B cells (CD19⁺CD27⁺IgD⁺), memory B cells (CD19⁺CD27⁺IgD⁻), and plasmablasts (CD19⁺CD24⁻CD38⁺⁺),¹² Th1 cells (CD3⁺CD4⁺CD45RA⁻CXCR5⁻CXCR3⁺CCR6⁻), Th17 cells (CD3⁺CD4⁺CD45RA⁻CXCR5⁻CXCR3⁻CCR6⁺), recent thymus emigrant T cells (RTE, CD3⁺CD4⁺CD45RA⁺CD31⁺), circulating Tfh cells (cTfh, CD3⁺CD4⁺CD45RA⁻CXCR5⁺), and Treg cells (CD3⁺CD4⁺CD25⁺CD127^{low}).

For Phosflow-cytometry studies in T cells, peripheral blood mononuclear cells (PBMCs) were stained with anti-CD3 and anti-CD28 antibodies (1 μ g/mL, BioLegend, San Diego, CA, USA), followed by crosslinking with goat-anti-mouse IgG (10 μ g/mL, BD Biosciences) for stimulation at 37 °C. Cells were mixed with Phosflow Lyse/Fix buffer, followed by permeabilization with Phosflow Perm buffer III (both from BD Biosciences) and stained with the following antibodies: anti-phospho-S6 (#4851, Cell Signaling Technology, Danvers, MA, USA) and anti-CD3 (clone SK7, BioLegend).

Western blot

T cells were isolated from PBMCs using an immunomagnetic negative selection kit (StemCell Technologies, Vancouver, British Columbia, Canada), stained with anti-CD3 and anti-CD28 antibodies (1 μ g/mL; BioLegend), and crosslinked with goat anti-mouse IgG (10 μ g/mL, BD Biosciences) for stimulation at 37 °C. Cells were washed with cold phosphate-buffered saline (PBS) immediately and lysed in RIPA lysis buffer (Beyotime Biotechnology, Shanghai, China) containing protease inhibitor cocktail (Sigma–Aldrich, St. Louis, MO, USA) and PhosSTOP (Roche, Basel, Switzerland). Approximately 20 μ g total protein was resolved in 8% acrylamide/bis gels, transferred to polyvinylidene fluoride membranes, and probed with the following antibodies: anti-p110 δ (#34050), anti-AKT (#9272), anti-phospho-AKT S473 (#4060), and anti- β -actin (#12620). Horseradish peroxidase (HRP)-conjugated anti-rabbit IgG (#7074) was used as the secondary antibody. All antibodies were purchased from Cell Signaling Technology. Band intensities were quantified using ImageJ software (NIH, Bethesda, MD, USA).

Results

Clinical history of three patients with APDS1 presenting with SLE phenotype

Patient 1 (P1)

The patient is male. At the time of manuscript submission, he was 15 years of age. He is the younger of identical twins. At the age of 2 years, he began experiencing recurrent upper respiratory tract infection. At the age of 3 years, he was hospitalized with Coombs-positive hemolytic anemia, accompanied by hepatosplenomegaly and enlarged mesenteric lymph nodes. Hemoglobin was decreased to 75 g/L. Antinuclear antibodies (ANA) were negative. Both

anti-CMV and anti-EBV IgM/G were positive. Over the next few years, he continued to have recurrent Coombs-positive hemolytic anemia, respiratory tract infection, and lymphoproliferation, and was treated with low-dose glucocorticoids. At the age of 9 years and 8 months, he was admitted to our hospital for increased proteinuria (0.97 g/day). Renal biopsy showed deposition of IgM, IgG, IgA, C3, and C1q, and revealed stage III lupus nephritis. ANA were positive at 1:320. Tests for anti-double strand (ds)-DNA and anti-ribosomal P protein antibodies (ARPA) were positive. Complement fractions C3 and C4 were decreased (to 0.2 g/L [normal 0.704–1.700 g/L] and 0.06 g/L [normal 0.094–0.338 g/L], respectively). Coombs-positive hemolytic anemia was evident, with a hemoglobin concentration of 41 g/L. Decreased serum IgG and increased IgM were present (6.12 g/L [normal 6.432–15.408 g/L] and 3.96 g/L [normal 0.463–2.367 g/L], respectively). Flow cytometry demonstrated a decrease in CD4⁺ T cells (24%, normal: 27–51%) with an increase in CD8⁺ T cells (54%, normal 15–44%), which resulted in an inversion in the CD4:CD8 ratio (0.45, normal 0.7–2.8). Chest computed tomography (CT) showed pneumonia, segmental atelectasis, pulmonary fibrosis, pleural effusion, and pericardial effusion. Cardiac ultrasound showed both thickened ventricular septum and posterior wall of the left ventricle, wider inner diameter of the root of the aorta, and mild tricuspid regurgitation and pulmonary regurgitation. He was treated with pulse cyclophosphamide therapy three times with a poor response.

At 11 years and 5 months of age, the patient was readmitted for cardiac and renal insufficiency. Increases were evident in the levels of serum urea nitrogen (10.84 mmol/L, normal 2.2–7.14 mmol/L), creatinine (101 μ mol/L, normal 14–60 μ mol/L), and uric acid (528 μ mol/L, normal 100–410 μ mol/L). Increases were also evident in the levels of lactate dehydrogenase (402.6 U/L, normal 110–330 U/L) and alpha hydroxybutyrate dehydrogenase (351 U/L, normal 120–270 U/L). Creatine kinase level was decreased (31 U/L, normal 40–300 U/L). Serum IgG level was decreased (4.29 g/L, normal 6.432–15.408 g/L) and serum IgM level was increased (4.17 g/L, normal 0.463–2.367 g/L).

At the age of 13 years, cerebral hemorrhage occurred due to hypertension, which resulted in decreased muscular tone on the left side of the body. During the course of illness, he experienced recurrent oral ulcers and transient arthralgia. He is now receiving low-dose glucocorticoids regularly and often has respiratory infections. The Coombs's test and ANA are positive. Complement fractions are decreased. Persistent proteinuria and hematuria are presented. Next-generation sequencing of the genomic DNA for more than 5300 diseases included in the OMIM database revealed heterozygous mutations in *PIK3CD* (p.E1021K), but did not identify other susceptibility variants associated with SLE (The *PDCD1*, *IRF5*, *CR1*, *CR2*, *DNASE1L3*, *STAT4*, *TLR5* and *ITGAM* were included in the OMIM database for the analysis of SLE risk).

Patient 2 (P2)

The patient is the older brother of patient 1. At the age of 8 years, he was admitted to our hospital with SLE, lupus nephritis, Coombs-positive hemolytic anemia, and respiratory failure. Hemoglobin, lymphocyte count, and C3 were

decreased to 75 g/L, 0.68×10^9 /L, and 0.38 g/L, respectively. Direct Coombs's test was positive. ANA was positive (+++). The tests for anti-ds-DNA and anti-SS-A antibodies were positive. Anti-herpes simplex virus (HSV) and anti-EBV IgM/G were positive. Serum level of IgG was decreased (4.12 g/L, normal 6.432–15.408 g/L) and serum level of IgM was increased (3.84 g/L, normal 0.463–2.367 g/L). Flow cytometry demonstrated a decrease in CD4⁺ T cells (10%, normal 27–51%) with an increase in CD8⁺ T cells (79%, normal 15–44%), which resulted in an inversion in the CD4:CD8 ratio (0.13, normal 0.7–2.8). Proteinuria was increased at 0.76 g/day. Serum urea nitrogen level was increased (23.26 mmol/L, normal 2.2–7.14 mmol/L). Renal biopsy showed deposition of IgM, IgG, IgA, and C3, and revealed stage IV-V lupus nephritis. Blood pressure was high at 180/140 mmHg. Blood oxygen saturation was low at 86–92% with mask oxygen inhalation. Chest CT showed pneumonia, pleural lesions, pleural effusion, and pericardial effusion. Cardiac ultrasound showed mild pulmonary regurgitation, mitral regurgitation, and tricuspid regurgitation. The patient had oral ulcers, bilateral knee arthralgia, and hepatosplenomegaly during hospitalization.

He had suffered from recurrent respiratory tract infections, Coombs-positive hemolytic anemia, and chronic lymphadenopathy since the age of 2 years. He died in 2012 because of poor control of disease progression. Since patients 1 and 2 are identical twins, we speculate that they have the same gene mutation. Their parents were non-consanguineous and there is no family history of autoimmune diseases.

Patient 3 (P3)

The patient is male. At the time of manuscript submission, he was 10 years of age. At the age of 3 years, he began experiencing recurrent diarrhea, accompanied by upper respiratory tract infection and hepatosplenomegaly. Anti-EBV IgM and IgG were positive. ANA was negative. At the age of 5 years, intestinal tract biopsy revealed chronic active inflammation, follicular hyperplasia, and infiltration of plasma cells in the colonic mucosa. Disorder of the intestinal flora was detected. He was treated with mesalazine. The clinical response was good. At the age of 6 years, he was admitted to our hospital with pneumonia, otitis

media, and mumps. Both anti-CMV and anti-EBV IgM/G were positive. IgM level was increased (3.86 g/L, normal 0.463–2.367 g/L). ANA were positive at 1:100. The test for anti-ds-DNA was positive. Complement fractions C3 and C4 were decreased (0.63 g/L, normal 0.7–2.06 g/L and 0.1 g/L, normal 0.11–0.61 g/L, respectively). Chest CT showed bronchiectasia and fibrobronchoscopy showed chronic tracheitis and bronchitis. He was diagnosed APDS1 (p.E1021K) by Sanger sequencing performed in our hospital. Regular immunoglobulin replacement therapy commenced.

At the age of 9 years, he was readmitted to our hospital for prolonged periods of fever, an enlarged parotid, and submandibular glands. There was a red rash on his nose and on the right lower eyelid. Coombs-positive hemolytic anemia with a hemoglobin level of 115 g/L. ANA was positive at 1:320. The tests for anti-ds-DNA and ARPA were positive. Complement fraction C3 was decreased (0.52 g/L, normal 0.7–2.06 g/L). Proteinuria was increased to 0.36 g/day. Serum IgG and IgM levels were increased (22 g/L [normal 5.28–21.9 g/L] and 4.26 g/L [normal 0.48–2.26 g/L], respectively). Flow cytometry demonstrated a decreased prevalence of CD4⁺ T cells (23.64%, normal 27–53%) and increased prevalence of CD8⁺ T cells (55.8%, normal 19–34%), which resulted in an inversion of the CD4:CD8 ratio (0.42, normal: 0.98–1.94). Chest CT showed pneumonia, pericardial effusion, and localized pleural thickening. Abdomen ultrasonography showed abdominal effusion. Cardiac ultrasound showed mild pulmonary regurgitation and tricuspid regurgitation. Wrist and phalangeal arthralgia and oral ulcers were present. He underwent pulse glucocorticoids therapy for three times with a good response. The dose of glucocorticoids was gradually reduced until stopped. He is now receiving rapamycin and immunoglobulin replacement therapy regularly.

Sanger sequencing detected heterozygous c.G3061A in *PIK3CD* in peripheral leukocytes and oral mucosal cells from P1 and P3, suggesting the presence of a *PIK3CD* somatic mutation. P2 died prior to sample collection. P1 and P2 were identical twins, and we speculated that they harbor the same *PIK3CD* mutation (Fig. 1). Together with the first clinical manifestations (Table 1), three patients met diagnosis criteria of APDS1. Meanwhile, the clinical and laboratory

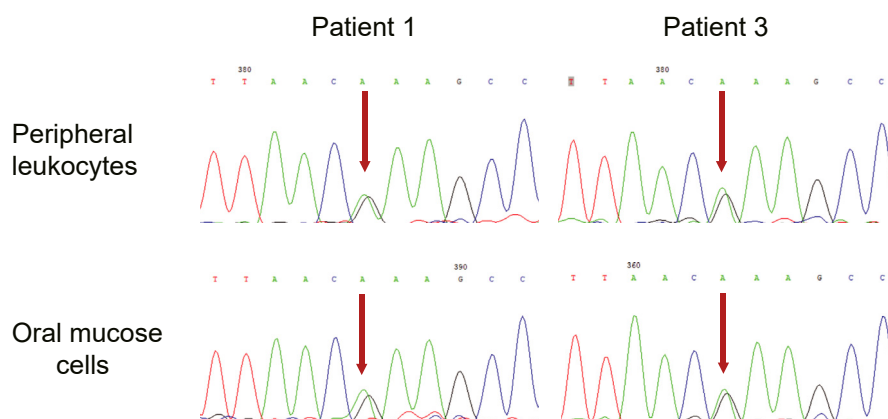


Figure 1 Patients with c.G3061A mutation in *PIK3CD*. Sequence chromatogram showing heterozygous mutation c.3061G > A in *PIK3CD* in peripheral leukocytes and oral mucosal cells from P1 and P3.

Table 1 Type of first clinical manifestations in three patients with APDS1 presenting with SLE phenotype.

Patient		P1	P2	P3
Age at onset (years)		2	2	3
Lung disease	Recurrent respiratory tract infections			
Recurrent otitis media				
EBV infection				
CMV infection				
HSV infection				
Nonneoplastic lymphoproliferation	Hepatomegaly			
	Splenomegaly			
	Chronic lymphadenopathy			
Intestinal disease	Recurrent diarrhea			
	Enteropathy			
Hematological abnormalities	Coombs ⁺ positive hemolytic anemia			
	Iron deficiency anemia			
Developmental retardation				

Each column represents a patient. Each row represents a clinical manifestation or a clinical examination.

White boxes and gray boxes depict the absence or presence of a complication, respectively

data also met diagnosis criteria of SLE of the American College of Rheumatology revised in 1997 (Table 2).¹³

Immunological features of patients with APDS1 presenting with and without SLE phenotype

The lymphocyte subset analysis in patients with APDS1 presenting with SLE phenotype (P1 and P3) showed a reversed ratio of CD4⁺ T cells to CD8⁺ T cells and a lower

distribution of naïve T cells. We observed B cell lymphocytopenia with lacked naïve B cells and showed enrichment for plasmablasts. The lymphocyte subset analysis in patients with APDS1 presenting without SLE phenotype (P4–P7) showed CD4⁺ T lymphocytopenia, a lower distribution of naïve T cells, and increased transitional B population (Table 3).

To further explore the differentiation of T cells, we analyzed the phenotype of its subsets in patients with SLE

Table 2 Diagnosis of SLE phenotype in patients 1, 2, and 3 according to the 1997 revised American College of Rheumatology criteria for SLE.

	Patient 1	Patient 2	Patient 3
Malar rash	no	No	yes
Discoid rash	no	No	no
Photosensitivity	no	No	no
Oral ulcers	yes	yes	yes
Non-erosive arthritis	transient arthralgia	bilateral knee arthralgia	wrist and phalangeal arthralgia
Pleuritis or pericarditis	pericardial effusion, pleural effusion	pericardial effusion, pleural effusion	pericardial effusion, localized pleural thickening
Renal disorder	24 h proteinuria 0.97 g, stage III lupus nephritis	24 h proteinuria 0.76 g, stage IV-V lupus nephritis	24 h urinary protein 0.36 g
Neurological disorder	cerebral hemorrhage, decreased muscular tone on left side of the body	No	no
Hematological disorder	HGB: 41 g/L, Ret: 0.144, LY: 0.32*10 ⁹ /L, positive Coombs test	HGB: 75 g/L, Ret: 0.062, LY: 0.68*10 ⁹ /L, positive direct Coombs test	HGB: 115 g/L, positive direct Coombs test
Immunological disorder	anti-dsDNA +, ARPA +, C3: 0.2 g/L (0.704–1.700), C4: 0.06 g/L (0.094–0.338)	anti-dsDNA ++, anti-SS-A +, C3: 0.38 g/L (0.704–1.700)	anti-dsDNA +, ARPA +, C3: 0.52 g/L (0.7–2.06)

HGB: hemoglobin, Ret: reticulocyte, LY: lymphocytes, dsDNA: double-stranded DNA, ARPA: anti-ribosomal P protein, C3: complement 3, C4: complement 4, ANA: antinuclear antibodies.

Table 3 Analysis of lymphocyte subpopulations in the peripheral blood from patients with and without SLE phenotype.

	P1	P2	P3	P4	P5	P6	P7
T cells/ μ l	568.9↓	612↓	1983.8	651.9↓	1454.8	989.5↓	1470.2
CD4 ⁺ T/ μ l	160.3↓	68↓	567.4	378.4↓	476.8↓	414.0↓	568.9↓
Naïve/ μ l	12.1↓	n.a.	47.7↓	66.2↓	65.8↓	61.7↓	123.4↓
CM/ μ l	124.4↓	n.a.	405.7	258.5	333.8	277.0	418.1
EM/ μ l	23.2↓	n.a.	112.3↑	52.2	70.6	74.5	23.2
Temra/ μ l	0.7	n.a.	1.5	1.4	6.6	0.6	4.4
CD8 ⁺ T/ μ l	382.6↓	537.2	1339.2↑	202.9↓	848.9	417.4↓	849.1
Naïve/ μ l	102.1↓	n.a.	151.3↓	96↓	149.4↓	45.1↓	247.9↓
CM/ μ l	62.7↓	n.a.	336.1↑	63.5↓	392.2↑	71.4↓	435.6↑
EM/ μ l	48.6	n.a.	330.8↑	19.9	149.4↑	131.1↑	82.3
Temra/ μ l	169.1	n.a.	521.0↑	23.3	157.9	169.9↑	83.6
CD4/CD8 ratio	0.45↓	0.13↓	0.42↓	1.86↑	0.56↓	0.99	0.67↓
B cells/ μ l	101↓	34↓	60.2↓	144.4↓	140.0↓	342.9	131.7↓
Transitional/ μ l	1.7↓	n.a.	10.7	72.5↑	39.3↑	180.0↑	96.8↑
Naïve/ μ l	32.1↓	n.a.	25.8↓	111.3	49.7↓	196.1	113.5↓
Memory/ μ l	51.7	n.a.	26.1↓	16.9↓	60.5	76.5	3.3↓
Plasmablasts/ μ l	33.6↑	n.a.	26↑	5.2	73.6↑	81.6↑	3.0↓

n.a., not available.

and without SLE phenotype. The frequencies of both non-circulating Tfh cells (non-cTfh) CD4⁺ memory T cells and cTfh cells were significantly increased in P1 and P3 compared with healthy controls and comparable with the frequencies in P4–P7. We observed the skewed levels of enriched Th1 cells and reduced Th17 cells within both non-cTfh CD4⁺ memory T cells and cTfh cells were comparable in patients with and without SLE phenotype (Fig. 2A). CD4⁺CD25⁺CD127^{low} population (Treg) from P3 and P4–P7 showed a reduction within CD4⁺ T cells, while it was comparable to that in health control from P1 (Fig. 2B). A decrease in RTE proportion within CD4⁺ T cells (Fig. 2C) and overexpression of CD57 on CD8⁺ T cells (Fig. 2D) were found for both patients with and without SLE compared with healthy controls.

To extend the analysis of defects in B cell differentiation, we further analyzed the phenotype of antibody class switch recombination in B cells. A significant fewer of IgG expression on B cells and IgG/A expression on memory B cells were found for both patients with and without SLE phenotype compared with healthy controls (Fig. 2E).

Immunosuppressive treatment in patients with APDS1

P1 was treated with low-dose glucocorticoids after three courses of pulsed cyclophosphamide therapy since 9 years of age. Phosphorylation of AKT at Ser473 (p-AKT) in T cell blasts from P1 was higher than that in HC before and after stimulation, while phosphorylation of S6 at Ser235/236 (p-S6) was lower (Fig. 3A). After pulsed therapy with glucocorticoids and maintenance therapy with low-dose glucocorticoids, p-AKT was hyperactive in T cell blasts from P3, while p-S6 was lower in T cell blasts from P3 than that in HC before and after stimulation (Fig. 3B).

To further verify whether treatment with glucocorticoids influenced p-S6, we sought to test the hypothesis in two other patients (P4 and P5) with APDS1 (p.E1021K) in our cohort, who were treated with low-dose glucocorticoids for cytopenia for 3–5 years. We found that p-AKT was hyperactive in T cell blasts from P4 before and after stimulation, while p-S6 was lower in T cell blasts from P4 than that in HC before stimulation, and further phosphorylation did not occur after stimulation (Fig. 3C). Hyperactive p-AKT and reduced p-S6 were also detected in T cell blasts from P5 before and after stimulation (Fig. 3D).

Next, we sought to evaluate p-AKT and p-S6 in other two patients (P6 and P7) with APDS1 (p.E1021K) who were treated with rapamycin for hepatosplenomegaly in our cohort. Both p-AKT and p-S6 in T cell blasts from P6 and P7 were decreased or comparable to that in HC before and after stimulation (Fig. 4A and B).

After long-term treatment with low-dose glucocorticoids, positive ANA, decreased complement fractions, Coombs-positive hemolytic anemia, persistent cytopenia, recurrent proteinuria and respiratory tract infections were still present in P1 and P2. Cytopenia and lymphoproliferation were responsive to glucocorticoids treatment in P4 and P5. Rapamycin had a benefit in the treatment of lymphoproliferation disease in P6 and P7. Now P3 is treated with rapamycin since stopped taking glucocorticoids. The clinical manifestations improved in P3 treated with rapamycin, showing a normal level of HGB and lymphocyte, and reduced frequency of pneumonia. His symptoms of pericardial effusion, abdominal effusion and proteinuria are gradually improved. However, positive ANA, positive Coombs test and low level of C3 have no change. Based on the immunological phenotype detected in P1–P7, no improvement in T/B cell differentiation and antibody class switch recombination was found upon treatment with these two immunosuppressive agents.

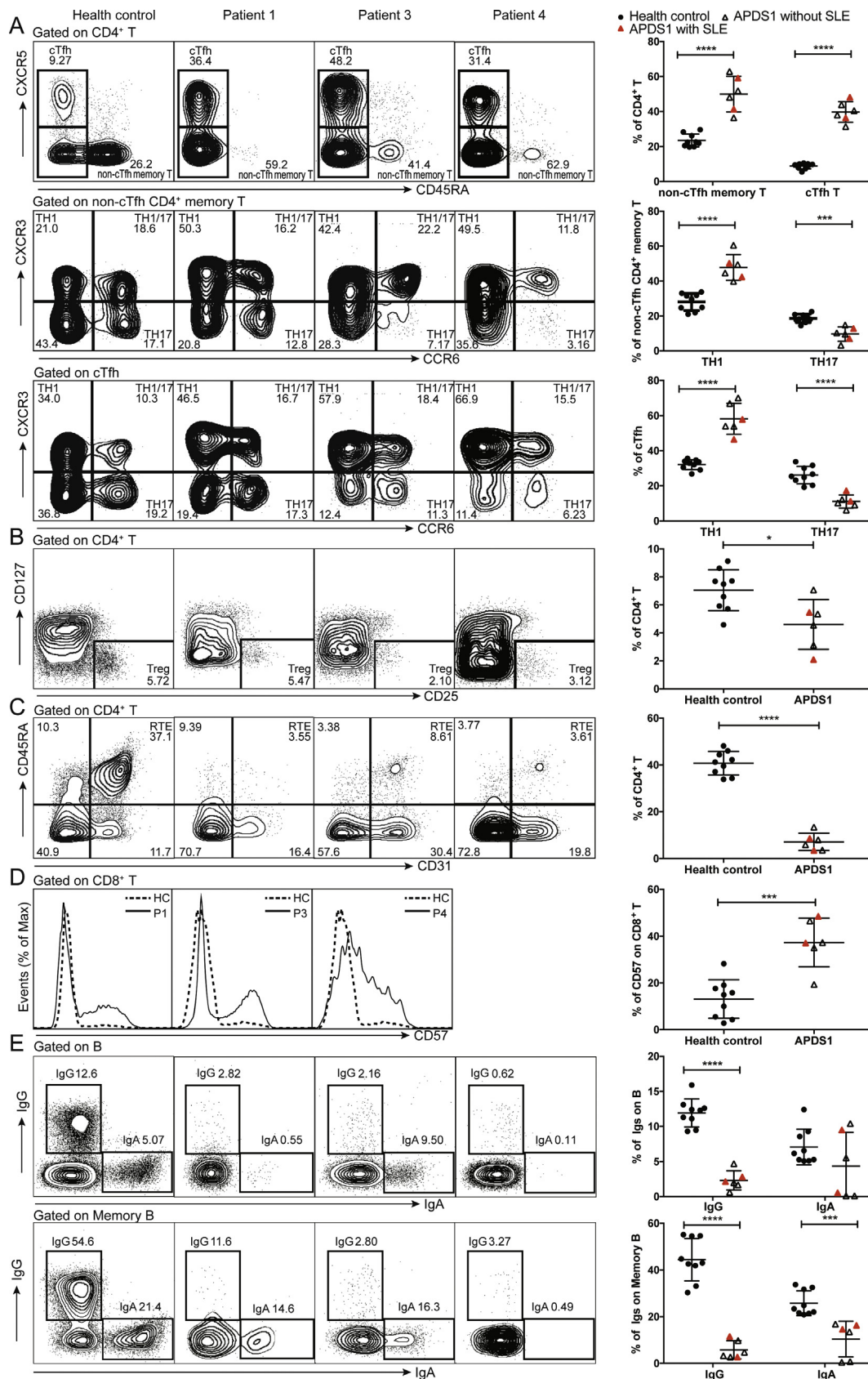


Figure 2 Main relevant findings in immunophenotyping in subsets of T cells and B cells from patients with SLE phenotype (P1–P3) and without SLE phenotype (P4–P7). **(A)** Proportions of non-cTfh memory cells and cTfh cells within the CD4⁺ T cell population; Percentages of Th1 cells and Th17 cells within the non-cTfh memory CD4⁺ T cell population and cTfh population. **(B)** Percentages of Treg cells within the CD4⁺ T cell population. **(C)** Percentages of RTE cells within the CD4⁺ T cell population. **(D)** CD57 expression on CD8⁺ T cells. **(E)** IgG and IgA expression on B cells and memory B cells.

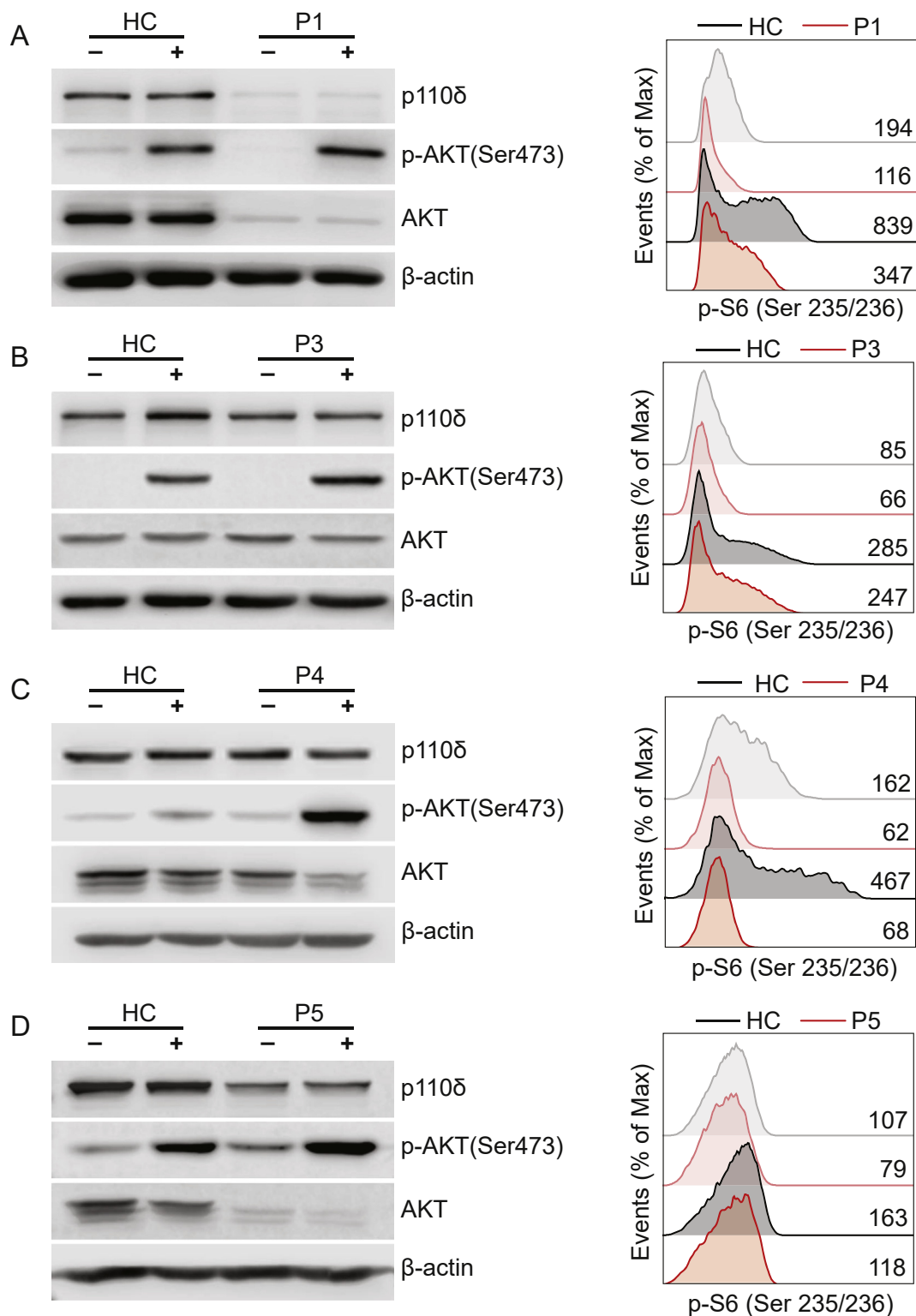


Figure 3 Immunoblot analysis for p-AKT (S473) and phospho analysis for p-S6 (S235/236) in T cell blasts. (A–D) The p-AKT and p-S6 analysis in T cell blasts from P1, P3, P4 and P5 with glucocorticoids treatment. The expression of p-S6 in T cell blasts from HCs (black line) and patients (red line) was assessed by mean fluorescence intensity before (light shade) and after (dark shade) stimulation. The number represent the mean fluorescence intensity.

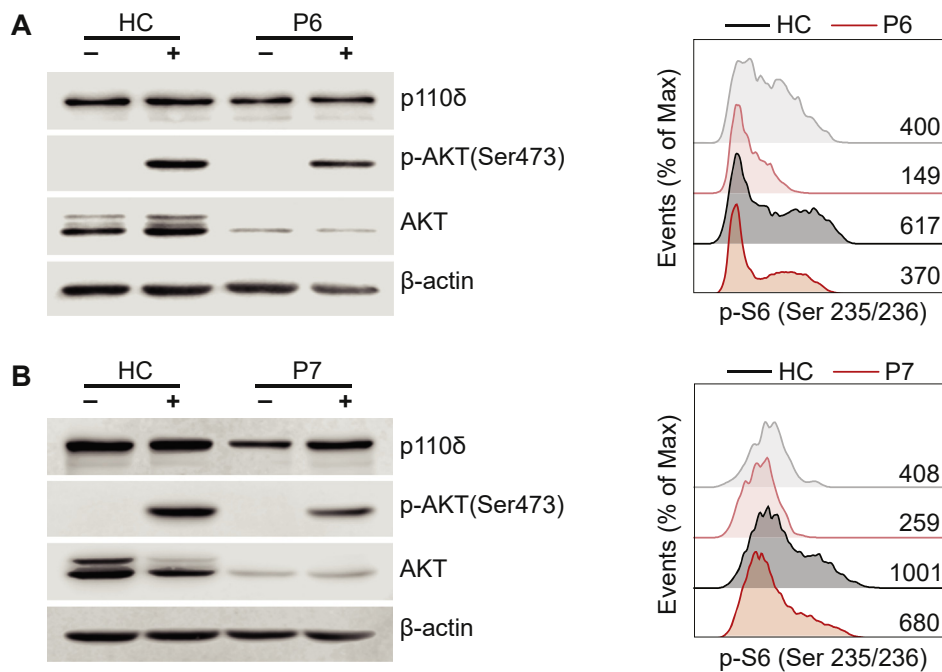


Figure 4 Immunoblot analysis for p-AKT (S473) and phospho analysis for p-S6 (S235/236) in T cell blasts (**A & B**) The p-AKT and p-S6 analysis in T cell blasts from P6 and P7 with rapamycin treatment. The expression of p-S6 in T cell blasts from HCs (black line) and patients (red line) was assessed by mean fluorescence intensity before (light shade) and after (dark shade) stimulation. The number represent the mean fluorescence intensity.

Discussion

We observed heterogeneous clinical manifestations in three patients with APDS1. These patients has not been reported previously. Some deregulated pathways and immune deficiency involved in PIDs have been implicated in the pathogenesis of SLE development. Patients with SLE are susceptible to infection because of immunological abnormalities and immunosuppressive treatment.¹⁴ The overlapping symptoms and the complexity of the clinical picture can delay or prevent diagnosis of SLE phenotype in PIDs. The most common manifestation in patients with APDS1 was recurrent infection and lymphoproliferation, the occurrence of autoimmune or inflammatory disease was rare. Whereas patients with APDS1 presenting with SLE phenotype had recurrent autoimmune or inflammatory disease along with recurrent infection and lymphoproliferation from the time of onset. The Coombs-positive hemolytic anemia, positive ANA, low level of complement and proteinuria were rarely developed in patients with APDS1.^{3,4}

SLE is a complex disease with immunologic abnormality, environmental factors, and genetic susceptibility contributing to its pathogenesis. Several studies have reported the involvement of appropriate phosphoinositide 3-kinase (PI3K) pathway maintenance in central and peripheral B cell tolerance. Sustained activation of the PI3K pathway mediated by conditional deletion of Pten in newly formed B cells results in altered negative selection and the egress of autoreactive B cells in the periphery and autoantibody production.^{15,16} Increased PI3K δ activity has been reported in patients with SLE, especially during the active phases of SLE.¹⁷

Expansion of the cTfh cells has been described in SLE patients and lupus mouse models, and increased levels of cTfh cells have been positively correlated with the levels of serum anti-dsDNA and ANA, as well as with increased disease activity.^{18–20} In parallel, skewing to Th1-like cTfh cells differentiation is inefficient for B cells in the production of high affinity class switched antibodies, long-lived plasma cells, and memory B cells.^{21,22} Moreover, expansion and disorganization of Tfh cells in the germinal center in *PIK3CD* GOF mice might diminish competition for the survival signals provided to B cells and impair specific responses.²³ These indicates that excessive differentiation of Tfh cells has been associated with the generation of autoimmunity and humoral immune deficiency in APDS1.

Basic treatment for patients with APDS1 include antibiotic and immunoglobulin replacement therapy.²⁴ Patients with autoimmune or inflammatory disease need immunosuppressive therapy. Treatment involving glucocorticoids can be beneficial in cytopenia.²⁵ We found that treatment with low-dose glucocorticoids inhibited the phosphorylation of S6, but the efficacy and side effects of glucocorticoids treatment with decreased p-S6 need further investigation. A partial good response to sirolimus (rapamycin) has been described in lymphoproliferative disease in patients with APDS1, but there is less benefit in using it to treat cytopenia and gastrointestinal disease.²⁶ Previous studies on the rapamycin treatment in patients with APDS1 showed a inhibition in Akt-mTOR signaling pathway.⁵ In our study, we observed decreased phosphorylation of Akt and S6 protein in P6 and P7. Although rapamycin treatment frequently abrogates mTORC1-mediated feedback inhibition of PI3K-AKT signaling, leading to a paradoxical enhancement

of AKT activity,²⁷ prolonged rapamycin treatment leads to inhibition of mTORC2 assembly.²⁸ In many cell types, prolonged rapamycin treatment reduces the levels of mTORC2 below those needed to maintain Akt/PKB signaling. It suggests that rapamycin can be used to inhibit Akt/PKB in certain cell types.^{29,30} However, the long-term effects of sirolimus therapy remain to be clarified. Specific PI3K δ inhibitor therapies reduce lymphoproliferation and improve immunological markers, but side effects of pneumonitis, transaminitis, and colitis have been reported. More clinical trials are needed to determine the best dose and means of delivery.²⁵ Because of progressive airway infection and bronchiectasis, hematopoietic stem cell transplantation may be a long-term treatment option for young patients.¹

Conclusion

Three patients with APDS1 presented with SLE phenotype enriched clinical phenotypes of APDS1 disease. Early diagnosis of the underlying disease is important for optimal treatment in PIDs presenting autoimmune diseases. Further studies are needed to identify diagnostic biomarkers and to explore the mechanism involved in the development of SLE phenotype in APDS1.

Authors contribution

Yanping Wang, Qiuyun Yang, Xuemei Chen, and Wenjing Tang performed experiments and analyzed the data. Lina Zhou and Zhi Chen provided help in performing the research. Yunfei an, Zhiyong Zhang and Xuemei Tang managed the patients. Yanping Wang and Xiaodong Zhao wrote the manuscript. Xiaodong Zhao designed the study and provided the financial supporting. All authors read and approved the final manuscript.

Conflict of Interests

The authors declare that they have no conflict of interest.

Funding

We thank the patients and their families for taking part in the study. We also thank the doctors, nurses, and other health care providers at the Children's Hospital of Chongqing Medical University. This work was supported by the Natural Science Foundation of China [grant number 81974255] and Science and Technology Research Program of Chongqing Municipal Education Commission, China [grant number KJZD-M201800401].

References

- Angulo I, Vadas O, Garçon F, et al. Phosphoinositide 3-kinase δ gene mutation predisposes to respiratory infection and airway damage. *Science*. 2013;342(6160):866–871.
- Lucas CL, Chandra A, Nejentsev S, Condliffe AM, Okkenhaug K. PI3K δ and primary immunodeficiencies. *Nat Rev Immunol*. 2016;16(11):702–714.
- Coulter TI, Chandra A, Bacon CM, et al. Clinical spectrum and features of activated phosphoinositide 3-kinase δ syndrome: a large patient cohort study. *J Allergy Clin Immunol*. 2017;139(2):597–606.
- Jamee M, Moniri S, Zaki-Dizaji M, et al. Clinical, immunological, and genetic features in patients with activated PI3K δ syndrome (APDS): a systematic review. *Clin Rev Allergy Immunol*. 2020;59(3):323–333.
- Wang Y, Wang W, Liu L, et al. Report of a Chinese cohort with activated phosphoinositide 3-kinase delta syndrome. *J Clin Immunol*. 2018;38(8):854–863.
- Elkaim E, Neven B, Bruneau J, et al. Clinical and immunologic phenotype associated with activated phosphoinositide 3-kinase δ syndrome 2: a cohort study. *J Allergy Clin Immunol*. 2016;138(1):210–218.
- Li GM, Liu HM, Guan WZ, et al. A mutation in PIK3CD gene causing pediatric systemic lupus erythematosus: a case report. *Medicine (Baltimore)*. 2019;98(18):e15329.
- Tsokos GC, Lo MS, Reis PC, Sullivan KE. New insights into the immunopathogenesis of systemic lupus erythematosus. *Nat Rev Rheumatol*. 2016;12(12):716–730.
- Carneiro-Sampaio M, Liphauts BL, Jesus AA, Silva CA, Oliveira JB, Kiss MH. Understanding systemic lupus erythematosus physiopathology in the light of primary immunodeficiencies. *J Clin Immunol*. 2008;28(SUPPL 1):S34–S41.
- Jouhadi Z, Khadir K, Ailal F, et al. Ten-year follow-up of a DOCK8-deficient child with features of systemic lupus erythematosus. *Pediatrics*. 2014;134(5):e1458–e1463.
- Aeschlimann FA, Batu ED, Canna SW, et al. A20 haploinsufficiency (HA20): clinical phenotypes and disease course of patients with a newly recognised NF- κ B-mediated auto-inflammatory disease. *Ann Rheum Dis*. 2018;77(5):728–735.
- Ding Y, Zhou L, Xia Y, et al. Reference values for peripheral blood lymphocyte subsets of healthy children in China. *J Allergy Clin Immunol*. 2018;142(3):970–973.
- Hochberg MC. Updating the American College of Rheumatology revised criteria for the classification of systemic lupus erythematosus. *Arthritis Rheum*. 1997;40(9):e1725.
- Sawada T, Fujimori D, Yamamoto Y. Systemic lupus erythematosus and immunodeficiency. *Immunol Med*. 2019;42(1):1–9.
- Di Cristofano A, Kotsi P, Peng YF, Cordon-Cardo C, Elkon KB, Pandolfi PP. Impaired Fas response and autoimmunity in Pten(+/-) mice. *Science*. 1999;285(5436):2122–2125.
- Browne CD, Del Nagro CJ, Cato MH, Dengler HS, Rickert RC. Suppression of PI(3,4,5)P3 production is a key determinant of B cell anergy. *Immunity*. 2009;31(5):749–760.
- Suárez-Fueyo A, Barber DF, Martínez-Ara J, Zea-Mendoza AC, Carrera AC. Enhanced phosphoinositide 3-kinase δ activity is a frequent event in systemic lupus erythematosus that confers resistance to activation-induced T cell death. *J Immunol*. 2011;187(5):2376–2385.
- Blanco P, Ueno H, Schmitt N. T follicular helper (Tfh) cells in lupus: activation and involvement in SLE pathogenesis. *Eur J Immunol*. 2016;46(2):281–290.
- Zhang X, Lindwall E, Gauthier C, et al. Circulating CXCR5+CD4+ helper T cells in systemic lupus erythematosus patients share phenotypic properties with germinal center follicular helper T cells and promote antibody production. *Lupus*. 2015;24(9):909–917.
- Tangye SG, Ma CS, Brink R, Deenick EK. The good, the bad and the ugly-T FH cells in human health and disease. *Nat Rev Immunol*. 2013;13(6):412–426.
- Bier J, Rao G, Payne K, et al. Activating mutations in PIK3CD disrupt the differentiation and function of human and murine CD4+ T cells. *J Allergy Clin Immunol*. 2019;144(1):236–253.
- Morita R, Schmitt N, Bentebibel SE, et al. Human blood CXCR5(+)CD4(+) T cells are counterparts of T follicular cells

- and contain specific subsets that differentially support antibody secretion. *Immunity*. 2011;34(1):108–121.
23. Preite S, Cannons JL, Radtke AJ, et al. Hyperactivated PI3K δ promotes self and commensal reactivity at the expense of optimal humoral immunity. *Nat Immunol*. 2018;19(9):986–1000.
 24. Michalovich D, Nejentsev S. Activated PI3 kinase delta syndrome: from genetics to therapy. *Front Immunol*. 2018;9:e369.
 25. Coulter TI, Cant AJ. The treatment of activated PI3K δ syndrome. *Front Immunol*. 2018;9:e2043.
 26. Maccari ME, Abolhassani H, Aghamohammadi A, et al. Disease evolution and response to rapamycin in activated phosphoinositide 3-kinase δ syndrome: the European society for immunodeficiencies-activated phosphoinositide 3-kinase δ syndrome registry. *Front Immunol*. 2018;9:e543.
 27. O'Reilly KE, Rojo F, She QB, et al. mTOR inhibition induces upstream receptor tyrosine kinase signaling and activates Akt. *Cancer Res*. 2006;66(3):1500–1508.
 28. Rosner M, Hengstschläger M. Cytoplasmic and nuclear distribution of the protein complexes mTORC1 and mTORC2: rapamycin triggers dephosphorylation and delocalization of the mTORC2 components rictor and sin1. *Hum Mol Genet*. 2008;17(19):2934–2948.
 29. Chi H. Regulation and function of mTOR signalling in T cell fate decisions. *Nat Rev Immunol*. 2012;12(5):325–338.
 30. Sarbassov DD, Ali SM, Sengupta S, et al. Prolonged rapamycin treatment inhibits mTORC2 assembly and Akt/PKB. *Mol Cell*. 2006;22(2):159–168.